



## CASE REPORT

### AN INCIDENTAL FINDING OF DISSECTING AORTIC ANEURYSM IN 63 YEAR OLD MALE; CASE REPORT



<sup>1</sup>Ani NE, <sup>2</sup>Bassey DE, <sup>3</sup>Jinadu FO, <sup>4</sup>Ikpeme AA, <sup>5</sup>Echieh CP

<sup>1</sup>Department of radiology, University of Calabar teaching hospital UCTH, Calabar, Nigeria

<sup>2</sup>Department of radiology, University of Calabar teaching hospital UCTH, Calabar, Nigeria

<sup>3</sup>Department of radiology, Lagos State University teaching Hospital UCTH, Lagos, Nigeria

<sup>4</sup>Department of radiology, University of Calabar teaching hospital UCTH, Calabar, Nigeria

<sup>5</sup>Department of Surgery, Cardio -thoracic unit, University of Calabar teaching hospital UCTH, Calabar, Nigeria

#### ABSTRACT

Aortic dissection is one of the acute aortic syndromes and a type of arterial dissection. The term Acute Aortic Syndrome (AAS) is used to describe a spectrum of life-threatening aortic emergencies of the thoracic aorta: classic Aortic Dissection (AD), Intramural Hematoma (IMH) and Penetrating Atherosclerotic Ulcer (PAU)<sup>1,2</sup>. Aortic dissection starts with a tear in the intima of the aortic lining. The tear allows a column of blood under pressure to enter the aortic wall, forming a haematoma. Hemorrhage in the media (at vasa vasorum) leads to either a tear in the weakened intima which breaks into the lumen or hemorrhage separates media from adventitia<sup>1,2,3</sup>. The false lumen extends for a variable distance in either direction.

The most common sites for the intimal tear are within 2-3 cm of the aortic valve or distal to the left subclavian artery in the descending aorta<sup>2</sup>.

The incidence of aortic dissection is approximately 3-4 per 100,000 per year<sup>2, 3</sup>. Aortic dissection is the most common emergency affecting the aorta. The incidence is about 3:1 male to female predominance.

It is most common between the ages of 50-70, being rare below the age of 40. The age of the index case falls within this range (63 years). Aortic dissection is very rare in children but it has been reported in association with coarctation of the aorta<sup>2</sup>

Aortic dissection is a medical emergency and can quickly lead to death, even with optimal treatment, as a result of decreased blood supply to other organs, heart failure, and sometimes rupture of the aorta. Aortic dissection is more common in those with a history of high blood pressure, a known thoracic aortic aneurysm, and in a number of connective tissue diseases that affect blood vessel wall integrity such as Marfan syndrome and the vascular subtype of Ehlers-Danlos syndrome. Other risk factors include structural aortic abnormalities such as bicuspid aortic valve, aortic coarctation, Turner syndrome, pregnancy, intra-aortic balloon pumps, infection (salmonella, typhoid and syphilis), trauma (decelerating injuries), takayasu and giant cell arteritis<sup>3,4</sup>.

The diagnosis is made with medical imaging (computed tomography, magnetic resonance imaging or echocardiography).

This case is being presented to highlight the essence of prompt request of imaging modality a patient who presents with recurrent chest pain, treated as a chronic case of dyspepsia without due investigations who was eventually seen to suffer from aortic dissection.

**KEYWORDS:** aortic dissection, false lumen, chest pain  
NigerJMed2016

#### CASE REPORT

A 63 year old retired teacher presented several times to the medical out-patient department of our hospital with repeated history of dull, retrosternal chest pain of 2 years duration. He occasionally suffered generalized abdominal pain and was treated a case of chronic peptic ulcer disease. Patient is neither a known hypertensive nor diabetic; nil history of fainting attacks during any of such visits. Family and social history was not contributory. Four months prior to the last presentation, he

was rushed to the medical emergency with history of sudden onset of tearing retrosternal chest pain. Hematological, biochemical tests and a basic chest x-ray were requested.

The hematological indices were normal aside from a low packed cell volume of 24%. The biochemical profile including serum lipid profile was also within normal limit.

The Chest X-ray showed a grossly unfolded and dilated aorta with double density shadow, overlying a normal sized heart. The aortic unfolding seems to have begun from the aortic

arch with extension to the descending thoracic aorta. No atheromatous plaque was seen within the aortic lumen. The lung fields were clear and pulmonary vasculature appeared within normal limits.

The managing physicians on seeing the chest x-ray report admitted the patient, referred him to the cardiothoracic unit for further evaluation; computed tomography was requested; contrast enhanced and angiography. The patient vehemently refused admission, insisting he was fine and did not require any admission but however agreed to carry out the said investigations on an outpatient basis. This he did, two weeks after.

The computerized tomographic angiogram revealed an anterograde aortic dissection originating from the arch of aorta, propagated all the way to the iliac bifurcation, giving the appearance of a double barrel aorta. The patient was duly counseled as to the implications of the findings, given some medications, educated on lifestyle modification and placed on regular follow up visits. Patient never turned up for any of the appointment and is presumed lost to follow up or worse still feared dead.

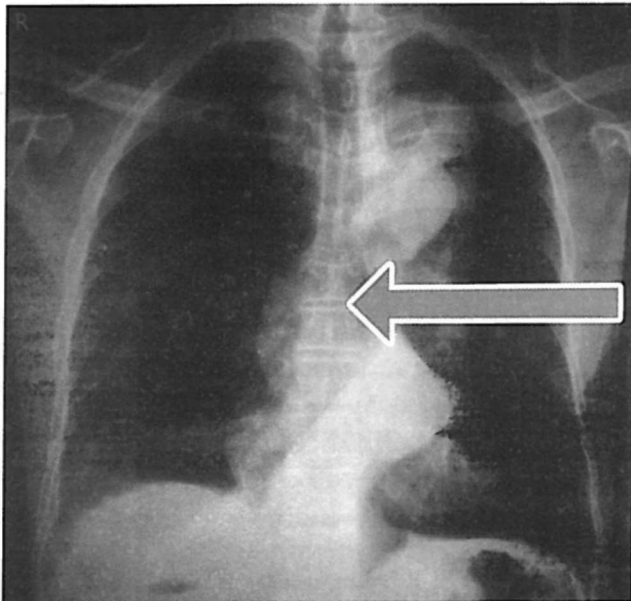


Fig. 1: Chest X-ray (PA) reveals a grossly unfolded aorta with lobulated outline and double density shadow overlying the heart, not silhouetting the left cardiac border.(see arrow)

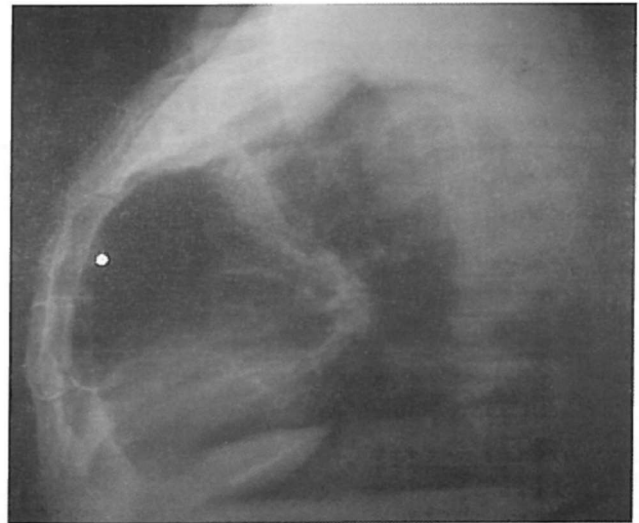


Fig. 2: Right lateral chest x-ray showing reduced retrosternal space superiorly by the dilated aorta as well as thoracic spondylotic changes.

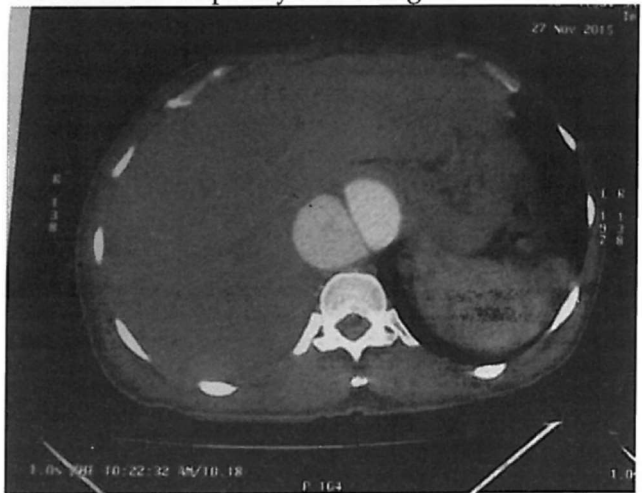

Fig. 3: Contrast-enhanced axial CT image demonstrates an intimal flap separating the two channels in the descending aorta diagnostic of a Stanford type A dissection.

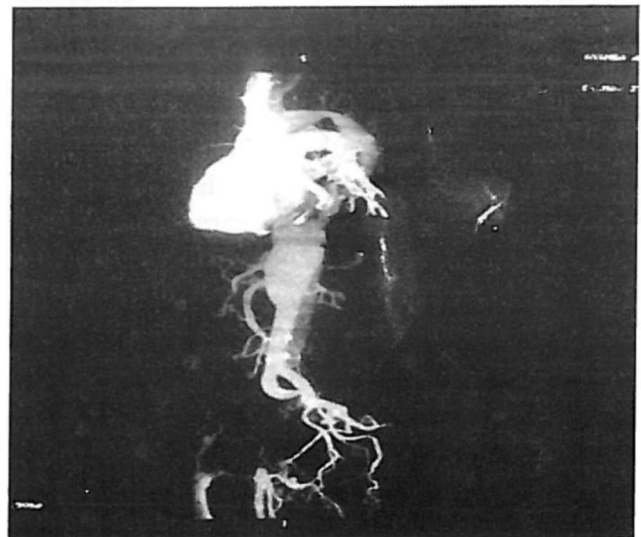


Fig. 4 is a 3D reconstructed computerized angiogram of the aorta, rotated in opposite direction to show the dissection clearly: It reveals Anterograde dissections originating from the aortic arch, propagated all the way to the iliac bifurcation of the aorta, and recanalizing the intravascular lumen leading to a double barrel aorta.

## DISCUSSION

Aortic dissections are arbitrarily divided into acute (first 14 days of onset of symptoms) and chronic (after 14 days of onset of symptoms)<sup>3</sup>. Chronic dissection are seen in individuals who do not present with pain.<sup>2,3</sup>

The clinical presentation of aortic dissection include; hypertension with anterior or posterior chest pain and a tearing sensation in the chest. The individual may be normotensive or hypotensive. Our index patient was normotensive. Symptoms that may suggest end organ ischemia may be present. These findings are often dependent on the extent of dissection and occlusion of branches (seen in up to 27% of cases). Commonly reported are abdominal organ ischemia, limb ischemia, ischemic or embolic stroke (involvement of artery of Adamkiewicz). In some cases of aortic rupture, the involvement of coronary arteries may result in collapse and death. Symptoms of cardiac tamponade (Beck's triad) may also be seen<sup>3,4,5</sup>. The index case complained of generalized abdominal pain, probably due to abdominal organ ischemia.

About 96% of individuals with aortic dissection present with severe pain that are of sudden onset, often described as tearing, stabbing, or sharp in character<sup>5</sup>. 17% of individual's pain migrates as the dissection extends down the aorta. The location of pain is associated with the location of the dissection<sup>3, 4</sup>. Anterior chest pain is associated with dissections involving the ascending aorta, while inter-scapular (back) pain is associated with descending aortic dissections. Pleuritic pain may suggest acute pericarditis caused by bleeding into the pericardial sac. This is a particularly dangerous eventuality, suggesting that acute pericardial tamponade may be imminent. The index case

complained of dull retrosternal chest pain and occasional generalized abdominal pain, no history of anterior chest pain despite the extensive involvement of the ascending aorta. The severity of the pain was not sufficient enough to incapacitate the patient, which was probably why he trivialized the outcome of the investigations.

The pain due to aortic dissection may be confused with the pain of a myocardial infarction (heart attack), but aortic dissection is usually not associated with the other signs that suggest myocardial infarction, including heart failure and ECG changes. The index case suffered from only recurrent retrosternal chest pains; ECG findings were also normal.

There are a number of important features about the pain; in aortic dissection, pain is abrupt in onset and maximal at the time of onset. In contrast, the pain associated with acute myocardial infarction starts slowly and gains in intensity with time. It is usually more oppressive and dull. The pain is said to migrate as the dissection progresses. In proximal dissections, the pain is usually retrosternal, but with distal dissections the location is between the scapulae and in the back. Although tearing is the classical description associated with aortic dissection, the pain is described as sharp more often than tearing, ripping, or stabbing.

Pericardial tamponade is the most common cause of death from aortic dissection<sup>1, 2, 3</sup>. There were no features to suggest pericardial tamponade in the index case.

The pathophysiology of aortic dissection shows that blood penetrates the intima and enters the media layer. The high pressure rips the tissue of the media apart along the laminated plane splitting the inner 2/3 and the outer 1/3 of the media apart<sup>2,4,6</sup>. This can propagate along the length of the aorta for a variable distance forward or backwards. Dissections that propagate towards the iliac bifurcation (with the flow of blood) are called anterograde dissections and those that propagate towards the aortic root (opposite of the flow of blood) are called retrograde dissections<sup>1-7</sup>. The initial tear is usually within 100 mm of the aortic valve so a retrograde dissection can easily compromise the pericardium leading to a hemocardium.

Anterograde dissections may propagate all the way to the iliac bifurcation of the aorta, rupture the aortic wall, or recanalize into the intravascular lumen leading to a double barrel aorta. The double barrel aorta relieves the pressure of blood flow and reduces the risk of rupture. Rupture leads to hemorrhaging into a body cavity and the prognosis depends on the area of rupture. Retroperitoneal and pericardial ruptures are both possible<sup>5,7,8</sup>. The index case is thought to be an anterograde dissection. Hypertension is typically associated with distal aortic dissection; this was not the case with our index patient.

The vast majority of aortic dissections originate with an intimal tear in either the ascending aorta (65%), the aortic arch (10%), or just distal to the ligamentum arteriosum in the descending thoracic aorta (20%).

Imaging is essential in delineating the morphology and extent of the dissection as well as allowing for classification (which dictates management). Two classification systems are in common usage, both of which divide dissections according to involvement of the ascending aorta namely the Stanford classification and DeBakey classification.

Stanford Type A lesions involve the ascending aorta and aortic arch and may or may not involve the descending aorta.

Stanford Type B lesions involve the thoracic aorta distal to the left subclavian artery. The Stanford classification has replaced the DeBakey classification (type I= ascending, arch and descending aorta especially seen in patients less than 65 years: type II= only ascending aorta: type III= only descending aorta commonly seen in hypertensives and atherosclerotics). The index case appears to be a Stanford type 1 and he is 63 years old.

Treatment options for the 2 subgroups of the acute aortic dissection are very different: Stanford type A will be treated with surgery or endovascular therapy while Stanford Type B will be treated medically<sup>7,8</sup>.

The reason for surgical repair of Type A

dissections is that ascending aortic dissections often involve the aortic valve, which, having lost its suspensory support, telescopes down into the aortic root, resulting in aortic incompetence. This needs re-suspending to reseat the valve and repair / prevent coronary artery injury. Also the area of dissection is removed and replaced with a Dacron graft to prevent further dissection from occurring. However type B dissections are not improved, from a mortality point of view, by operation, unless there is leaking, rupture or compromise to other organs, example, kidneys, spleen.<sup>5,7</sup>

Chest radiography may be normal, or demonstrate a number of suggestive findings, including widened mediastinum, double aortic contour, irregular aortic contour, inward displacement of atherosclerotic calcification. The chest x-ray of the index case, revealed a normal size heart, grossly unfolded aorta with a double aortic contour, atheromatous plaque was not seen within the aortic lumen.

Computerized Tomography, especially with arterial contrast enhancement (CTA) is the investigation of choice, able not only to diagnose and classify the dissection but also evaluate for distal complications. It has reported sensitivity and specificity of nearly 100%<sup>3,5</sup>.

Non-contrast CT may demonstrate only subtle findings; however, high density mural haematoma is often visible. Displacement of atherosclerotic calcification into the lumen is also a frequently identified.

Post contrast CT (CTA preferably) gives excellent detail. Findings may include<sup>1,3,5</sup>: intimal flap, double lumen and dilatation of the aorta. The diagnosis in the index case was made using contrast enhanced computerized tomography.

An essential part of the assessment of aortic dissection is identifying the true lumen, as placement of an endoluminal stent graft in the false lumen can have dire consequences. Often distinguishing between the two is obvious, but in some instances, no clear continuation of one lumen with normal artery can be identified. In such instances, a number of features are helpful<sup>3</sup>.

A true lumen is often compressed by the false lumen, outer wall calcifications (helpful in acute dissections) while a false lumen is often larger in size due to higher false luminal pressures

Chronic dissection flaps are often thicker and straighter than those seen in acute dissections<sup>3</sup>.

Trans-esophageal echocardiography (TOE) has very high sensitivity and specificity for assessment of acute aortic dissection, but due to limited access and invasive nature, it has largely been replaced by CTA or MRA in some<sup>5</sup>. TOE was not done for the index case due to non-availability in our center.

MRA has been reserved for follow-up examinations; rapid non-contrast imaging techniques (e.g. true FISP) may see MRI having a larger role to play in the acute diagnosis, particularly in patients with impaired renal function<sup>4</sup>. It has similar sensitivity and specificity to CTA and TOE<sup>5</sup> but suffers from limited availability and the difficulties inherent in performing MRI on acutely unwell patients.

Conventional digital subtraction angiography has historically been the gold standard investigation<sup>9</sup>. CTA has now replaced it as the first line investigation, not only due to it being non-invasive but also on account of better delineation of the poorly opacifying false lumen, intramural haematoma and end-organ ischaemia<sup>4,6,8</sup>.

Angiography although risky is still required for endoluminal repair. The risks of angiography include general risks of angiography plus risk of catheterizing the false lumen and causing aortic rupture.

On CT a number of entities can mimic a dissection these include; pseudo-dissection due to motion artifact and contrast streaks, mural thrombus, intramural haematoma: really an atypical type of aortic dissection, penetrating atherosclerotic ulcer.

Other differential diagnosis include: aortic regurgitation without dissection, aortic aneurysms without dissection, musculoskeletal

pain, pericarditis, mediastinal tumours, pleuritis, pulmonary embolism, cholecystitis, atherosclerotic or cholesterol embolism<sup>9</sup>.

## CONCLUSION

Aortic dissection is a rare distressing clinical condition with non-specific symptoms. It is reported with the hope of creating awareness of the need for prompt imaging for management of chronic chest pain and to heighten our index of suspicion when interacting with such patients.

## REFERENCES

1. Salvolini L, Renda P, Fiore D. Acute aortic syndromes: Role of multi-detector row CT. *Eur J Radio.* 2008; 65:350-358.
2. Aziz S, Ramsdale DR; Acute dissection of the thoracic aorta. *Hosp Med.* 2004 Mar; 65(3):136-42.
3. Thrumurthy SG, Karthikesalingam A, Patterson BO, et al; The diagnosis and management of aortic dissection. *BMJ.* 2011 Jan 11; 344-47
4. Kamalakannan D, Rosman HS, Eagle KA "Acute aortic dissection". *Crit Care Clin* . October 2007. 23 (4): 779-800.
5. Macura KJ, Corl FM, Fishman EK et-al. Pathogenesis in acute aortic syndromes: aortic dissection, intramural hematoma, and penetrating atherosclerotic aortic ulcer. *AJR Am J Roentgenol.* 2003; 181 (2): 309-16.
6. Blount KJ, Hagspiel KD. Aortic diameter, true lumen, and false lumen growth rates in chronic type B aortic dissection. *AJR Am J Roentgenol.* 2009; 192 (5): 222-229.
7. Lepage MA, Quint LE, Sonnad SS et-al. Aortic dissection: CT features that distinguish true lumen from false lumen. *AJR Am J Roentgenol.* 2001; 177 (1): 207-11
8. Pereles FS, McCarthy RM, Baskaran V. Thoracic aortic dissection and aneurysm: evaluation with non-enhanced true FISP MR Angiography in less than 4 minutes. *Radiology.* 2002; 223 (1): 270-274.
9. Hurwitz LM, Goodman PC. Intraaortic balloon pump location and aortic dissection. *AJR Am J Roentgenol.* 2005; 184 (4): 1245-6. *AJR Am J Roentgenol* (citation)